

STUDY OF CAROTICO-CLINOID FORAMEN IN DRY HUMAN SKULLS OF AURANGABAD DISTRICT

Sanobar I. Shaikh¹, Rahul K. Ukey², Deepak N. Kawale³, Chhaya V. Diwan⁴

ABSTRACT

The Carotico-clinoid foramen is an inconstant structure which is formed by the union of the anterior and middle clinoid processes by a ligament known as the carotico-clinoid ligament (CCL) which may be ossified. The present study is to know the prevalence of carotico-clinoid foramen in skulls of Aurangabad District.

For the present study, dry unknown human skulls from Aurangabad district, were collected in the Department of Anatomy, Government Medical College, Aurangabad. The carotico-clinoid foramen was studied in dry human skulls and was observed for various parameters like complete or incomplete, unilateral or bilateral. The data was analysed statistically with Chi square test. The presence of carotico-clinoid foramen was observed in 100 skulls and was found in 24 skull bones (24%). Complete bilateral carotico-clinoid foramen was found in 2 skulls (2%) and complete unilateral foramen was found in 2 skulls (2%), one on the right side and one on the left side. Incomplete bilateral carotico-clinoid foramen was found in 8 skulls (8%). Incomplete unilateral foramen was found in 8 skulls (8%), on right side, 7 skulls (7%) and left side, 1 skull (1%). Bilateral carotico-clinoid foramen, complete right side and incomplete left side was observed in 2 skulls (2%). Bilateral carotico-clinoid foramen, complete left side and incomplete right side was observed in 2 skulls (2%).

Variations in the anterior clinoid process (ACP) other than ossification are rare. The ossified carotico-clinoid ligament (CCL) may have compressive effects on the internal carotid artery. Thus anatomical knowledge of anterior clinoid process (ACP) and the clinoid space is of utmost importance for a neurosurgeon approaching the internal carotid artery or other skull based surgery. Excision of the ACP may be required for many skull based surgical procedures and the presence of any

anomalies such as ossified (CCL) may pose a problem for neurosurgeons.

Key words: Carotico-clinoid foramen, anterior clinoid process, middle clinoid process, carotico-clinoid ligament, clinoid space, internal carotid artery, skull based surgery.

INTRODUCTION

The Carotico-Clinoid Foramen (CCF) was first described by Henle (1855), as an osseous bridge between the tip of the middle and anterior clinoid processes¹. The medial end of the lesser wing of the sphenoid bone forms the Anterior Clinoid Process (ACP). The ACP provides attachment to the free margin of the tentorium cerebelli and is grooved medially by the internal carotid artery. The ACP is joined to the Middle Clinoid Process (MCP) by the Cortico-Clinoid Ligament (CCL), which is sometimes ossified. The ossification of CCL or of a dural fold extending between the ACP and MCP, may result in the formation of the Cortico-Clinoid Foramen (CCF). The existence of a bony or osseous CCF may cause compression, tightening or stretching of the internal carotid artery, especially of the clinoidal segment. Research studies have also reported the fact that an ossified CCL, makes the removal of anterior clinoid process more difficult, especially in the presence of an aneurysm⁸. In our study, we tried to know the prevalence of CCF, among the skull samples studied and to classify the foramen as complete unilateral or complete bilateral and incomplete unilateral or incomplete bilateral. Knowledge about the ossification of the CCL may be immensely beneficial for neurosurgeons.

METHODOLOGY

100 dry unknown human skulls were taken for the study.

The carotico-clinoid foramen was studied in the dry human skulls and were observed for the following parameters :

Presence/absence of the foramen .

Complete/incomplete foramen .

Unilateral/bilateral foramen .

STATISTICAL ANALYSIS

The data was analysed statistically with Chi- square test.

Graphs and tables were generated using microsoft office word and excel software .

INCLUSION CRITERIA-

Dry unknown human skulls which were well ossified were studied.

EXCLUSION CRITERIA

Fragmented broken skull bones and those with damaged clinoid process were excluded from the study.

RESULTS

Presence or absence of carotico-clinoid foramen: In 100 skulls used for the study, it was observed that in 24(24%) skull bones the carotico-clinoid foramen was present. Complete or incomplete CCF :It was found that amongst 100 skull bones, in 6 (6%) skulls, the CCF formed a complete foramen and in 18 (18%) skulls the CCF formed an incomplete foramen.

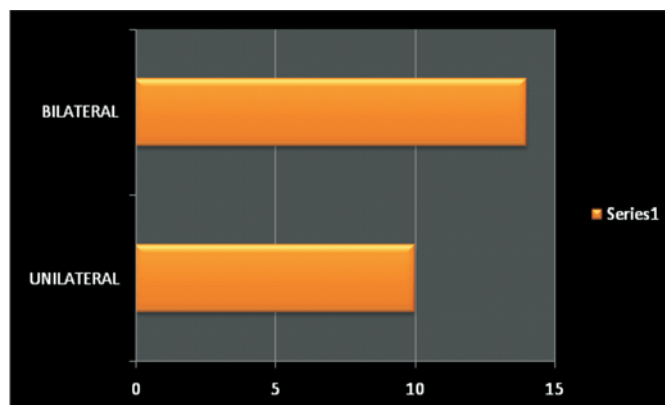
Bilateral and unilateral CCF : Bilateral CCF was found in 14 (14%) skull bones.

Unilateral CCF was found in 10 (10%) skull bones, amongst these in 8 (8%) skulls, the CCF was found on the right side and in 2 (2%) skulls, it was found on the left side.

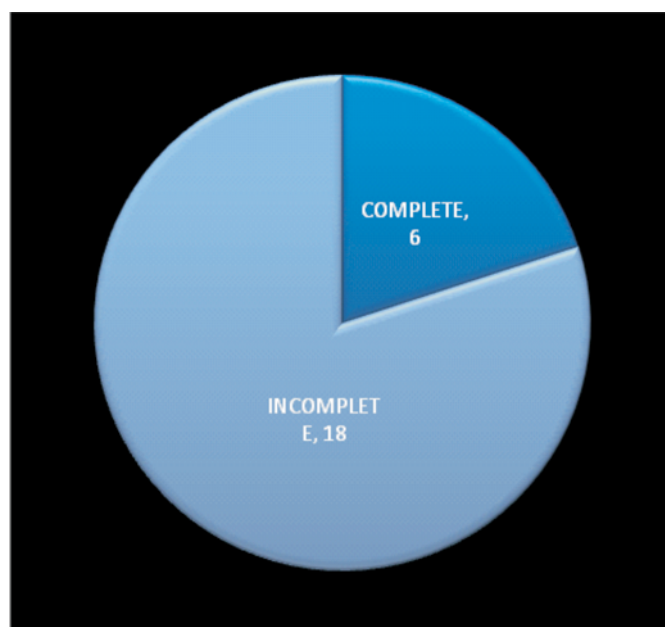
Moreover, in 4 skulls of Bilateral CCF, 2 skulls showed a Complete foramen on the right side and an Incomplete foramen on the left side and the rest 2 skulls showed a Complete foramen on the left side and an Incomplete foramen on the right side.

	SIDE	COMPLETE	INCOMPLETE	TOTAL
UNILATERAL	RIGHT	1	7	8
	LEFT	1	1	2
BILATERAL		2	8	10
BILATERAL	RIGHT	2	2	4
	LEFT	2	2	

TABLE-1: SHOWING COMPLETE, INCOMPLETE AND UNILATERAL, BILATERAL CAROTICO-CLINOID FORAMEN



GRAPH:1 SHOWING UNILATERAL AND BILATERAL CAROTICO-CLINOID FORAMEN



GRAPH:2 SHOWING COMPLETE AND INCOMPLETE CAROTICO-CLINOID FORAMEN

Statistically significant increase in the number of incomplete unilateral carotico-clinoid foramen was observed on the right ($p < 0.05$) compared to the left side . But equal number of complete unilateral carotico-clinoid foramen was observed on the right and the left sides .

AUTHOR	NO OF SPECIMEN	Caroticeclinoid foramen (CCF)		
		UNILATERAL	BILATERAL	TOTAL
Keyers(1935)	2187	--	--	27.46%
Azeredo et al. (1988)	270	6(2.22%)	11(4.05%)	17(6.27%)
Inoue et al. (1990)	50	11(22%)	7 (17%)	18 (36%)
Kee et al.(1997)	73	15.7%	1.4%	17.1%
Cireli et al. (1990)	50	3(6%)	--	3(6%)
Deda et al. (1992)	88	6(6.82%)	7(7.95%)	13(14.77%)
Guruset al. (1994)	198	16(8.08%)	11(5.55%)	27 (13.63%)
Erturk et al. (2002)	171	41(23.98%)	20(11.69%)	61 (35.67%)
Turkish Population (2004)	507	66(13.02%)	38 (7.5%)	104(20.51%)
Desai et al. (2010)	223	53 (23.74%)	30(13.45%)	83(37.19%)
Present study (2011)	100	10 (10%)	14 (14%)	24(24%)

TABLE-2: COMPARISON OF PRESENT STUDY RESULTS WITH OTHER STUDIES

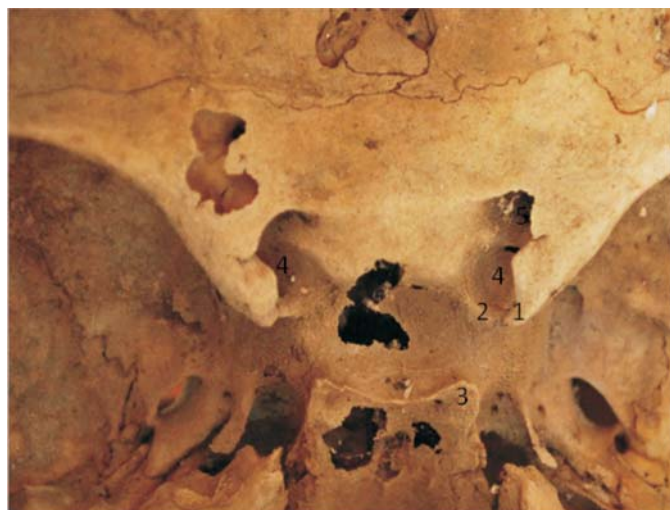

FIG-3: BILATERAL INCOMPLETE CAROTICO-CLINOID FORAMEN

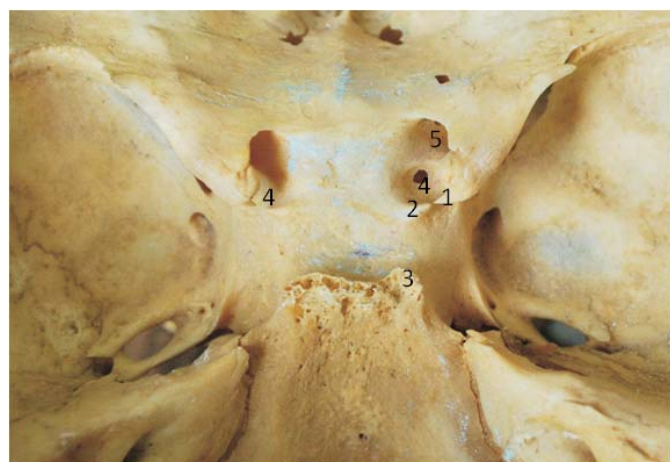

FIG-4: BILATERAL COMPLETE (LEFT) AND INCOMPLETE (RIGHT) CAROTICO-CLINOID FORMEN

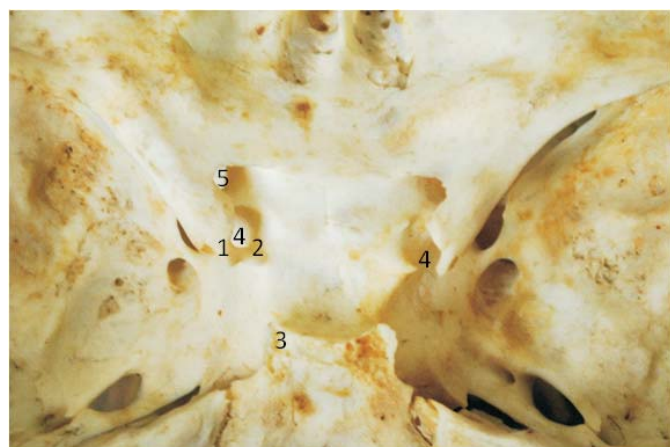


FIG-5: BILATERAL COMPLETE (RIGHT) AND INCOMPLETE (LEFT) CAROTICO-CLINOID FORAMEN

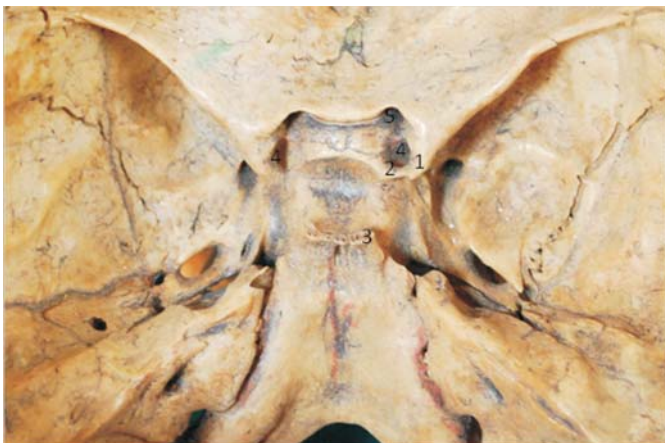

FIG-6: UNILATERAL COMPLETE CAROTICO-CLINOID FORAMEN (RIGHT)

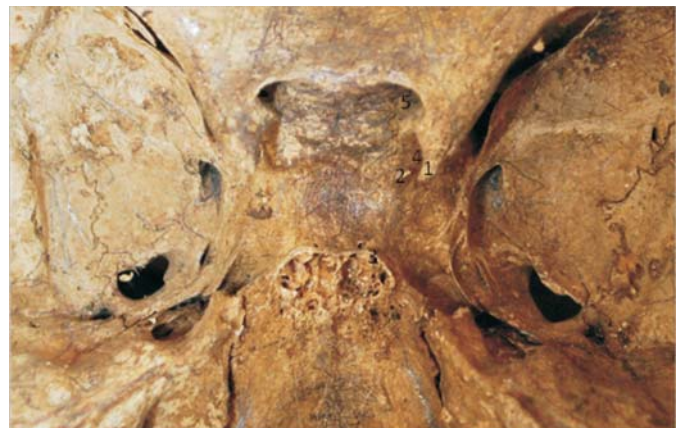

FIG-9: UNILATERAL INCOMPLETE CAROTICO-CLINOID FORAMEN (LEFT)

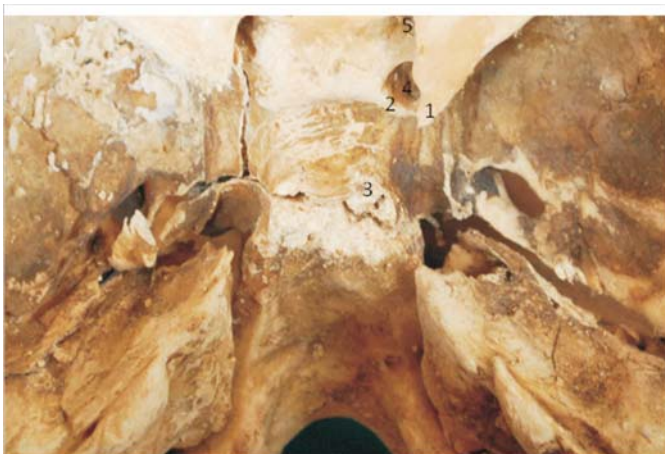
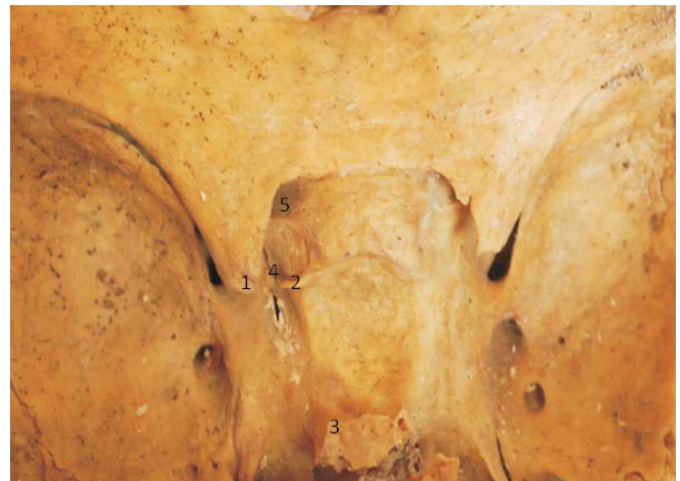
FIG-7: UNILATERAL COMPLETE CAROTICO-CLINOID FORAMEN (LEFT)



1. ANTERIOR CLINOID PROCESS
2. MIDDLE CLINOID PROCESS
3. POSTERIOR CLINOID PROCESS
4. CAROTICO-CLINOID FORAMEN
5. OPTIC CANAL

DISCUSSION

The ossification of fibrous ligaments is considered a normal physiological process that occurs with age (Erturk et al)¹.

However this process is an exception when one considers the formation of the carotico-clinoidforamen(CCF) (Donald,1998;Ozdogmus et al;Standring 2005).

Moreover the study by Hochstetter(1940)and Kier(1966)revealed the presence of this foramen in fetuses and children skulls².

Certain parts of the sphenoid bone are connected by ligaments, which occasionally ossify such as the pterygospinous (between the spine and the upper part of the lateral pterygoid plate), the interclinoid (between the anterior and the posterior clinoid processes) and the carotico-clinoid (between the anterior and the middle clinoid processes)³.

The carotico-clinoid foramen is the result of ossification either of the fibrous carotico-clinoid ligament or of a dural fold extending between the anterior and the middle clinoid processes of the sphenoid bone¹¹. When there is no ossification of the fibrous ligament, only a space between the anterior and middle clinoid processes is observed which is known as clinoid space¹¹.

The existence of a bony carotico-clinoid foramen may cause compression, tightening or stretching of the internal carotid artery. Changes in the internal carotid artery may cause compression of the cavernous sinus because of its medial position. [Narolewski, 2003; Gupta et al]. The study of Das et al showed that the presence of carotico-clinoid foramen causes morphological changes in the internal carotid artery especially of the clinoid segment, in almost all cases⁸.

The study of Ozdogmus et al demonstrated that due to calibre of the internal carotid artery in this area of the skull being larger than the diameter of carotico-clinoid foramen, it was reported that there is a high possibility to induce headache caused by compression of the internal carotid artery in the presence of carotico-clinoid foramen⁵.

In clinical practice, when a paraclinoid aneurysm occurs, the anterior clinoid process is removed as a treatment for this disease [Dolene, 1985, Inoue et al, 1990]. This treatment is more difficult when the carotico-clinoid foramen is present, causing higher possibility of serious bleeding in this region⁶.

After removal of the anterior clinoid process, a space is observed, the clinoid space, which has triangular form and small size⁴ (Gupta et al). This space varies according to dimension of the anterior clinoid process and the internal carotid artery⁷. (Sekhar & Akin, 1987).

Further, removal of the anterior clinoid process is one of the most critical procedures to the successful and safe management of ophthalmic segment aneurysms and tumours located in the paraclinoid region and cavernous sinus⁶. Besides that, pneumatization of the anterior clinoid process should be evaluated preoperatively with computed tomography to avoid complications such as rhinorrhea and pneumocephalous.

The presence or the absence of CCF was observed in 100 dry human skulls and it was found that in 24 skull bones (24%), the CCF was present.

Mete Erturk et al. reported in a study involving 119 adult dry skulls and 52 adult cadaveric heads of Turkish population that CCF was observed in 36.97% and 32.69% respectively; the total incidence being 61 (35.67%). Raveendranath V. Manjunath K. Y. and Remadevi R. observed out of 242 macerated skull bones of unknown sex, 34 (14.05%) skulls showed CCF which is less when compared to the present study.

Freire A. R; Rossi A. C., Prado F. B; Groppo F. C.; Caria P. H. F. and Botacin P. R. studied 80 dry human skulls and found 2.5% of the skulls with bilateral foramen and 6.25% with unilateral foramen, the total incidence of the foramen being 8.75% which is also less when compared to the present study.

In the present study, it was found that amongst 100 skull bones, in 6 (6%) skulls the CCF formed a complete foramen and in 18 (18%) skulls the CCF formed an incomplete foramen. Erturk M., in 119 dried human skulls in 52 cadavers, observed the complete-type CCF in 14 (4.09%) of the specimens, and incomplete type in 51 (14.91%) which is similar when compared to the present study.

Raveendranath V. Manjunath K. Y. and Remadevi R. found that amongst 242 macerated skull bones, 9.92% of the skulls showed a complete CCF and 4.13% of the skulls showed an incomplete CCF.

Desai S. D., Sunkeswani Sreepadma studied 223 skull bones and found that 39 (17.47%) skulls, the CCF formed a complete foramen, and in 44 (19.71%) skulls, CCF formed an incomplete foramen.

Lee H. Y's study in 73 dried Korean skulls, complete

CCF was observed in 4.1% and an incomplete type was observed in 11.6% which is similar to the present study.

In the present study, bilateral CCF was found in 14 (14%) skulls bones and unilateral CCF was found in 10 (10%) skull bones. Desai S.D., Sunkeswari Sreepadma found that amongst 223 skull bones studied, 30 (13.45%) skull bones showed bilateral CCF and 53(23.74%) skull bones showed unilateral CCF. ErturkM., evaluating bony and cadaveric specimens together, the total incidence of CCF was 35.67% and 20(11.69%) for bilateral CCF and 41(23.98%) for unilateral. In both these studies the incidence for bilateral CCF is similar but the incidence for unilateral CCF is more than the present study.

In the present study, unilateral CCF was found in 8 skulls (8%) on the right side and in 2 skulls (2%), it was found on the left side. The incidence of the foramen was higher on the right side than on the left side. In a study done by Desai S.D. Sunkeswari Sreepadma, unilateral CCF was found in 29 skulls (12.99%) on the right side and in 24 skulls (10.75%), it was found on the left side.

A Turkish study, by ErturkM., showed the incidence of unilateral CCF on the right side was 24 (12.28%) and on the left side it was 21 (11.7%).

In both the above studies the incidence of unilateral CCF was a little higher on the right side when compared with the left side.

In the present study, bilateral CCF was found in 14 skulls (14%). Out of these, complete bilateral CCF was found in 2 skulls (2%) and incomplete bilateral CCF was found in 8 skulls (8%). In the remaining 4 skulls, 2 skulls showed complete foramen on the right side and incomplete foramen on the left side and the rest 2 skulls showed complete foramen on the left side and incomplete foramen on the right side.

Unilateral CCF was found in 10 skulls (10%) out of these, complete unilateral CCF was found in 2 skulls (2%), out of which, 1 skull (1%) showed CCF on the right side and remaining 1 skull (1%) showed CCF on the left side. Incomplete unilateral CCF was found in 8 skulls (8%), amongst these 7 skulls (7%) had

incomplete foramen on the right side and only 1 skull (1%) had incomplete left CCF. The prevalence of incomplete unilateral CCF was more on the right side compared to the left side, whereas in case of complete unilateral CCF, the prevalence was equal on both the sides.

Desai S.D. and Sunkeswari Sreepadma in their study of 223 skull bones, reported the presence of CCF in 83 (37.19%) cases. Complete bilateral CCF was found in 23 skulls (10.31%) and incomplete bilateral CCF was found in 7 skulls (3.13%).

Complete unilateral CCF was found in 16 skulls (7.16%), out of which 9 skulls (4.03%) showed complete CCF on the right side and 7 skulls (3.13%) showed complete CCF on the left side. Incomplete unilateral CCF was found in 37 skulls (16.58%), amongst these, 20 skulls (8.96%) had incomplete foramen on the right side and 17 skulls (7.62%) had incomplete left CCF.

In both complete unilateral and incomplete unilateral CCF, they observed that the presence of this foramen is more on the right side compared to the left side. These findings are partly similar to the present study.

Conclusion

Knowledge of the prevalence of carotico-clinoid foramen helps the neuro-surgeons for pre-operative scanning and precautions can be taken to prevent fatal complications during surgery. Considering the fact that the anatomy text books do not provide a detailed description of the carotico-clinoid ligament or foramen, the present study proves especially relevant to neurosurgeons in day to day clinical practice.

Further, removal of the anterior clinoid process is an important step in regional surgery, for which additional risk is involved. Therefore detailed anatomical knowledge of the Carotico-Clinoid Foramen is of utmost importance, to increase the success of regional surgery.

BIBLIOGRAPHY

1. Erturk M., Kayalioglu G., Gousa F. Anatomy of the clinoidal region with special emphasis on the carotico-clinoid foramen and interclinoid

- osseous bridge in a recent Turkish population. *Neurosurg Rev* 2004;27:22-6.
2. Kier, E.L. Embryology of the normal optic canal and its anomalies. An anatomic and roentgenographic study. *Invest. Radiol*, 1:346-62, 1966.
 3. Dr. S.D. Desai, Dr. Sunkeswari Sreepadma. Study of carotico-clinoid foramen in dry human skulls of North Interior Karnataka. *NJBMS Oct-Dec 2010*; vol 1:2,60-4.
 4. Gupta N, Ray B, Ghosh S. A study on anteriorclinoid process and optic strut with emphasis on variations of carotico-clinoid foramen. *Nepal Med Coll J*. 2005;7(2):141-4.
 5. Ozdogmus O, Saka E, Tulay C, Gurdal E, Uzun I, Cavdar S. The anatomy of the carotico-clinoidforamen and its relation with the internal carotid artery. *SurgRadiolAnat* 2003;25(3-4):241-6.
 6. Dolene, V.V. A combined epi and subdural direct approach to carotidophthalmic artery aneurysms. *J.Neurosurg* 1985;5:667-72.
 7. Sekhar, L.N. and Akin, O. Anatomical study of the cavernous sinus emphasizing operative approaches and related vascular and neural reconstruction. *J.Neurosurg*, 1987;21:806-16.
 8. Das S., Suri R., Kapur V. Ossification of carotico-clinoid ligament and its clinical importance in skull based surgery. *Sao Paulo Med.J.Nov 2007*;125(6): 351-3.
 9. Raveendranath V., Manjunath K.Y. and Remadevi R. Incidence of Carotico-Clinoid Foramen in South Indian Skulls. *ANAMS*, 2010; 46(1).
 10. Freire, A.R., Rossi, A.C., Prado, F.B.Groppo, F.C., Caria, P.H.F. and Botacin, P.R. Carotico-clinoid foramen in Humanskulls, Incidence, Mophometry and its Clinical Implications. *Int.J.Morphol*, 2011; 29(2)427-31.
 11. Freire, A.R., Rossi, A.C., Prado, F.B.Groppo, F.C., Caria, P.H.F. and Botacin, P.R. The carotico-clinoid foramen in the human skull and its clinical correlations. *Case Report. IJAV*, 2010 ;3:149-50.
 12. Lee H.Y., Chung I.H., Choi B.Y. Anterior clinoid process and optic strut in Koreans. *Yonsei Med J*, 1997;38:151-4.

1. **Sanobar I. Shaikh**
Associate Professor, Department of Anatomy
Govt. Medical College, Aurangabad.
2. **Rahul K. Ukey**
Senior Resident, Department of Anatomy,
Govt. Medical College, Aurangabad.

3. **Deepak N. Kawale**
Senior Resident, Department of Anatomy,
Govt. Medical College, Aurangabad.
4. **Chhaya V. Diwan**
Professor and Head, Department of Anatomy
Govt. Medical College, Aurangabad.